

5. Baseggio M, Petinataud F, Callet-Bauchu E, et al: CD5 positive splenic marginal zone lymphoma: Clinical, cytological, immunological, molecular, and cytogenetical features of a series of 35 cases. *Haematologica* 92:104, 2007 (abstr 0288)

6. Chacón JI, Mollejo M, Muñoz E, et al: Splenic marginal zone lymphoma: Clinical characteristics and prognostic factors in a series of 60 patients. *Blood* 100:1648-1654, 2002

7. Oscier D, Owen R, Johnson S: Splenic marginal zone lymphoma. *Blood Rev* 19:39-51, 2005

8. Camacho FL, Mollejo M, Mateo MS, et al: Progression to large B-cell lymphoma in splenic marginal zone lymphoma: A description of a series of 12 cases. *Am J Surg Pathol* 25:1268-1276, 2001

9. Parry-Jones N, Matutes E, Gruszka-Westwood AM, et al: Prognostic features of splenic lymphoma with villous lymphocytes: A report on 129 patients. *Br J Haematol* 120:759-764, 2003

DOI: 10.1200/JCO.2008.17.6172

Complete Remission of Psoriasis After Autologous Hematopoietic Stem-Cell Transplantation for Multiple Myeloma

A 35-year-old white man with a 15-year history of psoriasis vulgaris and psoriatic arthropathy presented with vomiting, abdominal pain, anemia, acute renal failure, severe hypercalcemia, and numerous bony lytic lesions. Further testing confirmed the diagnosis of multiple myeloma with immunoglobulin A kappa restriction. A transient remission of the disease was achieved with bortezomib and dexamethasone treatment. The disease relapsed 4 months later, and the patient had a partial response after a modified regimen of cyclophosphamide, vincristine, doxorubicin, and dexamethasone. The treatment team decided to proceed with autologous peripheral hematopoietic stem-cell transplantation (HSCT). The psoriasis care in the pretransplant period was limited to phototherapy, topical agents such as calcipotriene, and topical corticosteroids (clobetasol, desonide, and triamcinolone). Despite the autoimmune nature of psoriasis,¹ the patient was not a candidate for systemic immunosuppressive therapy because of the cytotoxicity of the agents used to treat the multiple myeloma. Immediately before his stem-cell transplant, the numerous

symmetrically distributed erythematous plaques with silvery scales of psoriasis vulgaris covered 50% of the body-surface area, involving mainly the scalp, forehead, ears, back (Figs 1A and 1C), upper chest (Fig 1B), and abdomen (Fig 1D). Additional guttate plaques with scale affected the extensor surface of the elbows and knees, and the nails exhibited distal onycholysis. The patient had a long 15-year history of arthralgias and oligoarticular spondyloarthritis. The patient received a 2-day standard myeloablative conditioning with intravenous melphalan (100 mg/m² on day -3 and day -2 before HSCT followed by autologous peripheral HSCT (on day 0). Of note, the corticosteroids and phototherapy for the psoriasis have been discontinued before the time of HSCT because of risks of cumulative toxicity. Also, since the patient had an autologous HSCT, he did not receive any of the immunosuppressive agents usually used in cases of allogeneic transplants. The patient experienced a 1-year complete remission of myeloma, accompanied by complete regression of his psoriatic arthropathies and skin lesions though he was completely off corticosteroids and phototherapy. The patient also noted a complete resolution of the arthralgias from which he had suffered for more than a decade, despite remaining untreated for them. He remains psoriasis- and arthralgia-free 15 months later (Fig 2), although his myeloma has relapsed.

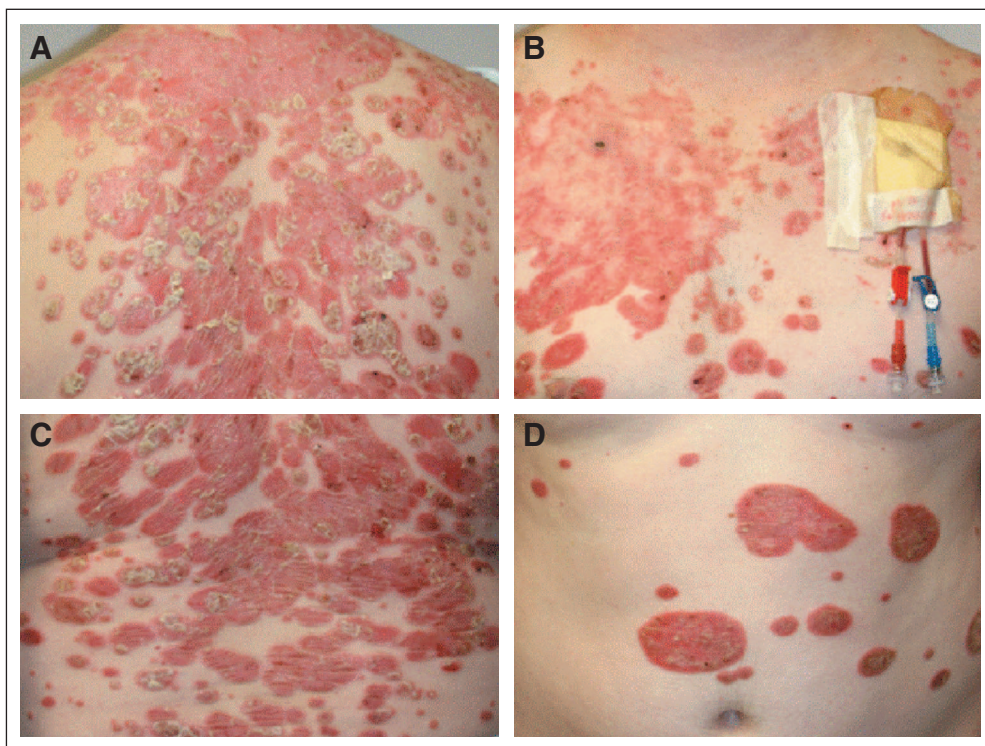


Fig 1.

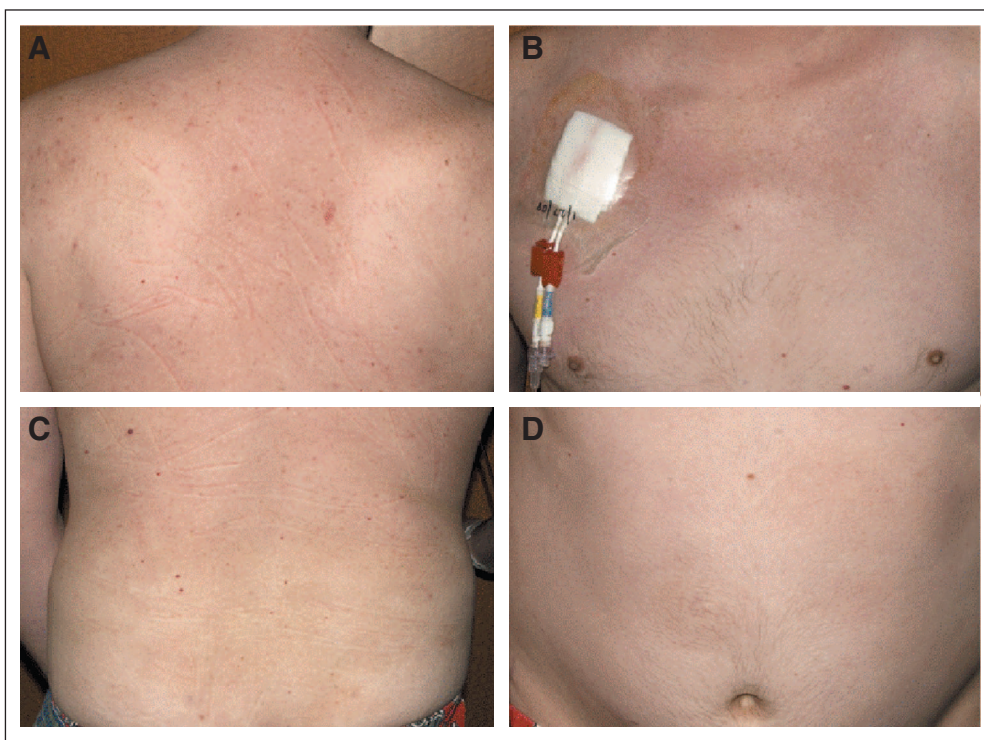


Fig 2.

Psoriasis is an autoimmune disease which affects the skin and joints.¹ The pathogenesis and therapeutic approaches to autoimmune disease remain a major clinical challenge. More than half a century ago, HSCT introduced a new arsenal of therapies into clinical practice, along with an array of complications. Indeed, autoimmune disease such as thyroiditis,² ulcerative colitis,^{3,4} psoriasis,⁵ and scleroderma⁶ occur occasionally after autologous HSCT. The development of autoimmune diseases after allogeneic HSCT and cord blood transplantation⁷ has been documented as well,^{5,8} such as thyroiditis, insulin-dependent diabetes mellitus, myasthenia gravis, and vitiligo. In the case of allogeneic transplants, the causal relationship between the HSCT and the autoimmune disease remains speculative, but the possibility of passive transfer of autoimmune disease from donor to recipient has raised interest in the role of T cells in regulating such diseases.⁹ In large part because of these findings, for the last decade, researchers have studied HSCT specifically for the treatment of autoimmune disease.¹⁰ Indeed, allogeneic HSCT, both with myeloablative and nonmyeloablative regimens,^{11,12} has demonstrated encouraging therapeutic results in treating psoriasis,¹³⁻¹⁵ rheumatoid arthritis,¹⁶ systemic lupus erythematosus,¹¹ and scleroderma.¹⁷ Whether a graft-versus-autoimmunity effect is a plausible therapeutic approach applicable to patient care remains conditional on the availability of less toxic nonmyeloablative regimens.¹⁸ Despite the negative reports of some development of a secondary autoimmune disease after autologous HSCT,¹⁹ most studies of transplants in patients already having autoimmune diseases have shown beneficial effects. When patients with concomitant long-standing autoimmune disease, were treated with autologous HSCT for hematological conditions (eg, aplasia or lymphomas), dramatic remissions were seen in the autoimmune disease.²⁰ The results from well-conducted, but limited, studies of autologous HSCT's therapeutic effects on concomitant autoimmune disease in patients with hematological disorders have been

mixed.^{21,22} In fact, responses of the autoimmune disease to autologous HSCT, with either myeloablative²³ or nonmyeloablative²⁴⁻²⁶ conditioning regimens, provided prolonged remissions. This was achieved in multiple sclerosis,^{20,27-29} scleroderma,^{26,30,31} autoimmune thrombocytopenic purpura,³² systemic lupus erythematosus,^{21,33} scleromyxedema,³⁴ Wegner's granulomatosis,^{35,36} and vasculitis.³⁵ Recent reports document that this benefit is not transient but is long lived as autologous HSCT provide sustained improvement of skin condition and organ function in scleroderma^{24,30,37-39} Why HSCT might have therapeutic value in autoimmune disease is still unclear.⁴⁰ In the case of autologous HSCT, since patients receive their own hematopoietic stem cells, the remission of autoimmune disease thereafter has been attributed to a resetting of the immunological memory. This immune modulation may be secondary to myeloablative conditioning, where high-dose chemotherapy eliminates self-reactive lymphocytes, resulting in ablation of the peripheral autoreactive and alloreactive T cells and depletion of thymus cells and reactive B cells. The subsequent decrease in the level of autoantibodies thus contributes to immune tolerance.⁴⁰ The reinfusion of autologous stem cells allows the establishment of lymphocytes *de novo*, which resets the arrangement of the different T-cell clones originally responsible for misrecognizing the auto-antigens as foreign antigens. Reconstitution of regulatory T cells and reactive B cells from naïve progenitors exposed to autoantigens may be responsible of regenerating self-tolerance.^{24,41,42} Additionally, autologous HSCT could increase cytokine production⁴³ and possibly play a role in regenerating tissues damaged by the inflammatory process.⁴¹

Fadi Braiteh

Division of Cancer Medicine, The University of Texas M. D. Anderson Cancer Center; Graduate School of Biomedical Sciences at the University of Texas in Houston, TX

Sharon R. Hymes

Department of Dermatology, The University of Texas M. D. Anderson Cancer Center, Houston, TX

Sergio A. Giral and Roy Jones

Department of Stem Cell Transplantation and Cellular Therapy, The University of Texas M. D. Anderson Cancer Center, Houston, TX

ACKNOWLEDGMENT

We thank Ms. Maude Veech for providing editorial review of the manuscript.

AUTHORS' DISCLOSURES OF POTENTIAL CONFLICTS OF INTEREST

The author(s) indicated no potential conflicts of interest.

REFERENCES

- de Rie MA, Goedkoop AY, Bos JD: Overview of psoriasis. *Dermatol Ther* 17:341-349, 2004
- Bohgaki T, Atsumi T, Koike T: Multiple autoimmune diseases after autologous stem-cell transplantation. *N Engl J Med* 357:2734-2736, 2007
- Koike K, Kohda K, Kuga T, et al: Ulcerative colitis after autologous peripheral blood stem cell transplantation for non-Hodgkin's lymphoma. *Bone Marrow Transplant* 28:619-621, 2001
- Steinbach WJ, Sandborg CI: Development of systemic lupus erythematosus following autologous bone marrow transplant for acute lymphocytic leukemia. *J Rheumatol* 28:1467-1468, 2001
- Wahie S, Alexandroff A, Reynolds NJ, et al: Psoriasis occurring after myeloablative therapy and autologous stem cell transplantation. *Br J Dermatol* 154:194-195, 2006
- Trad S, Amoura Z, Haroche J, et al: Fatal progressive systemic sclerosis following autologous stem cell transplantation and high-dose chemotherapy. *Rheumatology (Oxford)* 44:951-953, 2005
- Hubiche T, Leaute-Labreze C, Lepreux S, et al: Psoriasis after cord blood stem-cell transplantation. *Br J Dermatol* 156:386-388, 2007
- Kajinami K, Takekoshi N, Mabuchi H: Propranolol for probucol-induced QT prolongation with polymorphic ventricular tachycardia. *Lancet* 341:124-125, 1993
- Kishimoto Y, Yamamoto Y, Ito T, et al: Transfer of autoimmune thyroiditis and resolution of palmoplantar pustular psoriasis following allogeneic bone marrow transplantation. *Bone Marrow Transplant* 19:1041-1043, 1997
- Marmont AM: Stem cell transplantation for autoimmune disorders: Coincidental autoimmune disease in patients transplanted for conventional indications. *Best Pract Res Clin Haematol* 17:223-232, 2004
- Burt RK, Traynor A, Statkute L, et al: Nonmyeloablative hematopoietic stem-cell transplantation for systemic lupus erythematosus. *JAMA* 295:527-535, 2006
- Lu Q, Lu L, Niu X, et al: Non-myeloablative allogeneic stem-cell transplant in a patient with refractory systemic lupus erythematosus. *Bone Marrow Transplant* 37:979-981, 2006
- Chakrabarti S, Handa SK, Bryon RJ, et al: Will mixed chimerism cure autoimmune diseases after a nonmyeloablative stem-cell transplant? *Transplantation* 72:340-342, 2001
- He YL, Lu XJ, Qiu JY, et al: Severe vulgaris psoriatic patients with acute myelogenous leukaemia and resolution after allogeneic bone marrow transplantation/peripheral blood stem-cell transplantation. *Chin Med J (Engl)* 118:861-865, 2005
- Woods AC, Mant MJ: Amelioration of severe psoriasis with psoriatic arthritis for 20 years after allogeneic haematopoietic stem-cell transplantation. *Ann Rheum Dis* 65:697, 2006
- Snowden JA, Kearney P, Kearney A, et al: Long-term outcome of autoimmune disease following allogeneic bone marrow transplantation. *Arthritis Rheum* 41:453-459, 1998
- Nash RA, McSweeney PA, Crofford LJ, et al: High-dose immunosuppressive therapy and autologous hematopoietic cell transplantation for severe systemic sclerosis: Long-term follow-up of the US multicenter pilot study. *Blood* 110:1388-1396, 2007
- Kojima R, Kami M, Kim SW, et al: Induction of graft-versus-autoimmune (GVA) disease effect against refractory psoriasis by complete donor-type chimerism and graft-versus-host disease after allogeneic hematopoietic stem-cell transplantation. *Bone Marrow Transplant* 32:439-442, 2003
- Loh YS, Hwang WY, Ratnagopal P: Autologous haematopoietic stem-cell transplantation for the treatment of multiple sclerosis. *Ann Acad Med Singapore* 36:421-426, 2007
- Loh Y, Oyama Y, Statkute L, et al: Development of a secondary autoimmune disorder after hematopoietic stem-cell transplantation for autoimmune diseases: Role of conditioning regimen used. *Blood* 109:2643-2548, 2007
- Loh Y, Oyama Y, Statkute L, et al: Autologous hematopoietic stem-cell transplantation in systemic lupus erythematosus patients with cardiac dysfunction: Feasibility and reversibility of ventricular and valvular dysfunction with transplant-induced remission. *Bone Marrow Transplant* 40:47-53, 2007
- Tyndall A, Gratwohl A: Blood and marrow stem-cell transplants in autoimmune disease: A consensus report written on behalf of the European League against Rheumatism (EULAR) and the European Group for Blood and Marrow Transplantation (EBMT). *Bone Marrow Transplant* 19:643-645, 1997
- Cooley HM, Snowden JA, Grigg AP, et al: Outcome of rheumatoid arthritis and psoriasis following autologous stem-cell transplantation for hematologic malignancy. *Arthritis Rheum* 40:1712-1715, 1997
- Burt RK, Verda L, Oyama Y, et al: Non-myeloablative stem-cell transplantation for autoimmune diseases. *Springer Semin Immunopathol* 26:57-69, 2004
- Mohren M, Daikeler T, Benz D, et al: Myeloablative immunosuppressive treatment with autologous haematopoietic stem-cell transplantation in a patient with psoriatic arthropathy and monoclonal gammopathy of undetermined significance. *Ann Rheum Dis* 63:466-467, 2004
- Oyama Y, Barr WG, Statkute L, et al: Autologous non-myeloablative hematopoietic stem-cell transplantation in patients with systemic sclerosis. *Bone Marrow Transplant* 40:549-555, 2007
- Binks M, Passweg JR, Furst D, et al: Phase I/II trial of autologous stem-cell transplantation in systemic sclerosis: Procedure related mortality and impact on skin disease. *Ann Rheum Dis* 60:577-584, 2001
- Jayne D, Passweg J, Marmont A, et al: Autologous stem-cell transplantation for systemic lupus erythematosus. *Lupus* 13:168-176, 2004
- Su L, Xu J, Ji BX, et al: Autologous peripheral blood stem-cell transplantation for severe multiple sclerosis. *Int J Hematol* 84:276-281, 2006
- Farge D, Passweg J, van Laar JM, et al: Autologous stem-cell transplantation in the treatment of systemic sclerosis: Report from the EBMT/EULAR Registry. *Ann Rheum Dis* 63:974-981, 2004
- Tyndall A, Mueller-Ladner U, Matucci-Cerinic M: Systemic sclerosis in Europe: First report from the EULAR Scleroderma Trials And Research (EUSTAR) group database. *Ann Rheum Dis* 64:1107, 2005
- Elili E, Parma M, Perseghin P, et al: Successful treatment with T-depleted autologous peripheral blood stem-cell transplantation of refractory chronic autoimmune thrombocytopenic purpura. *Haematologica* 92:e7-e8, 2007
- Statkute L, Traynor A, Oyama Y, et al: Antiphospholipid syndrome in patients with systemic lupus erythematosus treated by autologous hematopoietic stem-cell transplantation. *Blood* 106:2700-2709, 2005
- Donato ML, Feasel AM, Weber DM, et al: Scleromyxedema: Role of high-dose melphalan with autologous stem-cell transplantation. *Blood* 107:463-466, 2006
- Kötter I, Daikeler T, Amberger C, et al: Autologous stem-cell transplantation of treatment-resistant systemic vasculitis: A single center experience and review of the literature. *Clin Nephrol* 64:485-489, 2005
- Tsukamoto H, Nagafuji K, Horiuchi T, et al: A phase I-II trial of autologous peripheral blood stem-cell transplantation in the treatment of refractory autoimmune disease. *Ann Rheum Dis* 65:508-514, 2006
- Gualandi F, Bruno B, Van Lint MT, et al: Autologous stem-cell transplantation for severe autoimmune diseases: A 10-year experience. *Ann N Y Acad Sci* 1110:455-464, 2007
- Nash RA, McSweeney PA, Nelson JL, et al: Allogeneic marrow transplantation in patients with severe systemic sclerosis: Resolution of dermal fibrosis. *Arthritis Rheum* 54:1982-1986, 2006
- Vonk MC, Marjanovic Z, van den Hoogen FH, et al: Long-term follow-up results after autologous haematopoietic stem-cell transplantation for severe systemic sclerosis. *Ann Rheum Dis* 67:98-104, 2008
- Dazzi F, van Laar JM, Cope A, et al: Cell therapy for autoimmune diseases. *Arthritis Res Ther* 9:206, 2007
- Sykes M, Nikolic B: Treatment of severe autoimmune disease by stem-cell transplantation. *Nature* 435:620-627, 2005
- Slavin S, Nagler A, Varadi G, et al: Graft vs autoimmunity following allogeneic non-myeloablative blood stem-cell transplantation in a patient with chronic myelogenous leukemia, severe systemic psoriasis, and psoriatic polyarthritis. *Exp Hematol* 28:853-857, 2000
- van der Velden AM, Claessen AM, Velzen-Blad H, et al: Development of T-cell-mediated immunity after autologous stem-cell transplantation: Prolonged impairment of antigen-stimulated production of gamma-interferon. *Bone Marrow Transplant* 40:261-266, 2007

DOI: 10.1200/JCO.2008.17.6560